13 Sexually Transmitted Diseases and Genital Infections

▼Table 18–13.0 Sexually Transmitted Diseases and Genital Infections

Pathogen	Description and Treatment
Klebsiella granulomatis	STD; gram-negative coccobacillus that causes **granuloma inguinale**
	Organism phagocytized by macrophages (**Donovan bodies**)
	Creeping, raised sore that heals by scarring; **no lymphadenopathy**
	Treatment: doxycycline or trimethoprim-sulfamethoxazole
Candida albicans 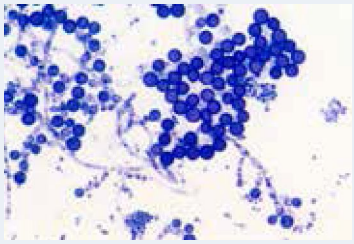	Yeasts and pseudohyphae (elongated yeasts); part of normal vaginal flora
	Second most common vaginitis in the U.S.
	Risk factors: diabetes, antibiotics, pregnancy, OCP
	Pruritic vaginitis with a **white discharge and fiery red mucosa**
	Treatment: fluconazole (single dose)
Chlamydia trachomatis	Third most common STD; often **coexists with *Neisseria gonorrhoeae* (45% of cases)**
	Incubation period 7–12 days after exposure; red inclusions (**reticulate bodies**) in infected **metaplastic squamous cells**; reticulate bodies divide to form **elementary bodies, which are the infective** bodies producing infection
	Infections in males: **N**on-**S**pecific **U**rethritis (NSU) (sterile pyuria), epididymitis, proctitis
	Infections in females: urethritis (sterile pyuria), cervicitis, PID, perihepatitis (**Fitz-Hugh-Curtis syndrome** scar tissue between peritoneum and surface of liver from pus from PID), proctitis, Bartholin gland abscess
	Infections in newborns: conjunctivitis (ophthalmia neonatorum), pneumonia
	DNA probe test for quick diagnosis; nucleic acid amplification test has the highest sensitivity and specificity
	Treatment: azithromycin 1 g (single dose); doxycycline
***C. Trachomatis* subspecies**	STD; **lymphogranuloma venereum**
	Papules and/or ulcerations
	Inguinal lymphadenitis with granulomatous microabscesses and draining sinuses
	Lymphedema of scrotum or vulva
	Women may have rectal strictures
	Treatment: doxycycline

Credit: Dr. Edward Chan/Visual's Unlimited, Inc.

© DeVry/Becker Educational Development Corp. All rights reserved.

▼Table 18–13.0 Sexually Transmitted Diseases and Genital Infections *(continued)*

Pathogen	Description and Treatment
Gardnerella vaginalis	Gram-negative rod that causes bacterial vaginosis
	Most common cause of vaginitis
	Douching alters the microenvironment by decreasing lactobacilli (gram-positive rods that produce lactic acid and the normal vaginal pH of 3.8–4.5)
	New or multiple sex partners also predisposes to this vaginitis, because the pH of semen is alkaline (7.2–7.8), which then creates an environment favorable for bacterial proliferation producing a malodorous vaginal discharge with a vaginal pH >4.5
	Organisms adhere to, but do not invade, squamous cells referred to as "clue cells"
	Increased incidence of preterm delivery and low-birth-weight newborns
	Treatment: metronidazole; same treatment in pregnancy
Haemophilus ducreyi	STD; gram-negative rod that causes **chancroid**
	Male dominant disease (10:1); high incidence of HIV
	Incubation 4–7 days
	Painful genital and perianal ulcers with suppurative inguinal nodes
	Diagnosis with Gram stain (**"school of fish"** appearance) and culture
	Treatment: ceftriaxone or azithromycin 1 g (single dose)
HSV-2	STD; virus remains latent in sensory ganglia
	Recurrent vesicles that ulcerate; locations—penis, vulva, cervix, perianal area
	Tzanck preparation: Scrapings removed from the base of an ulcer; see multinucleated squamous cells with eosinophilic intranuclear inclusions
	Pregnancy: If virus is shedding, baby is delivered by **cesarean section**
	Treatment: acyclovir (decreases recurrences)

Credits: (top to bottom) SPL/Science Source; Biophoto Associates/Science Source; Carolina Biological Supply Co./Visuals Unlimited, Inc.

© DeVry/Becker Educational Development Corp. All rights reserved.

▼Table 18–13.0 Sexually Transmitted Diseases and Genital Infections *(continued)*

Pathogen	Description and Treatment
HPV	STD; **types 6 and 11** (90%; low-risk types) associated with **condyloma acuminata** (venereal warts); **fernlike** or flat lesions in genital area (e.g., penis, vulva, cervix, perianal)
	Most common overall STD; 80% of sexually active women will have acquired HPV by age 50
	Types 16 and 18 (high-risk types) associated with **dysplasia and squamous cancer**
	Virus produces **koilocytic** change in squamous epithelium
	Cells have wrinkled pyknotic nuclei surrounded by a clear halo
	Approximately 90% spontaneously clear within two years (most within eight months); older women will more often have persistent disease
	Vaccine decreases risk for developing cervical cancer
	Treatment: topical podophyllin; α-IFN injection; imiquimod cream; sinecatechin ointment (botanical drug)
Neisseria gonorrhoeae 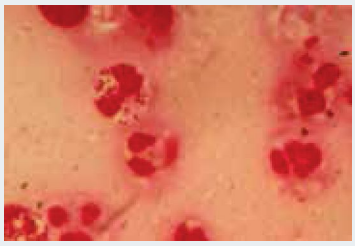	STD; gram-negative diplococcus that infects glandular or transitional epithelium; symptoms appear two to seven days after sexual exposure
	Infection sites similar to *C. trachomatis*
	Complications: ectopic pregnancy, male sterility, disseminated gonococcemia **(C6–C9 deficiency risk factor)**, septic arthritis, Fitz-Hugh-Curtis syndrome association
	Disseminated gonococcemia: septic arthritis (knee), tenosynovitis (hands, feet), pustules (hands, feet); more common in women than in men
	• DNA probe test for quick diagnosis • Nucleic acid amplification test has the highest sensitivity and specificity • Urethral swab in symptomatic males with Gram stain; endocervical swab for culture
	Treatment: ceftriaxone

Credits: (top to bottom) Dr. Ken Greer/Visuals Unlimited, Inc.; Leon J. LeBeau/Custom Medical Stock Photo

© DeVry/Becker Educational Development Corp. All rights reserved.

▼Table 18–13.0 Sexually Transmitted Diseases and Genital Infections *(continued)*

Pathogen	Description and Treatment
Treponema pallidum	STD; **gram-negative spirochete** that causes syphilis **Primary syphilis:** solitary **painless, indurated chancre;** locations—penis, labia, mouth
	Secondary syphilis: maculopapular rash on trunk, palms, soles; generalized lymphadenopathy; **condyloma lata,** which are flat lesions in the same area as condyloma acuminata; alopecia
	Tertiary syphilis: neurosyphilis, aortitis, **gummas**
	Congenital syphilis
	Nonspecific screening tests: RPR or VDRL; titers decrease after treatment
	Confirmatory treponemal test: FTA-ABS; positive with or without treatment
	Jarisch-Herxheimer reaction: intensification of rash in primary or secondary syphilis may occur due to proteins released from dead organisms after treatment with **penicillin**
	Treatment: penicillin
Trichomonas vaginalis	Current studies consider it to be the most common STD
	Flagellated protozoan with jerky motility in a wet prep of discharge
	Most women are asymptomatic or have a vaginal discharge
	Men are asymptomatic carriers who serve as a reservoir for infection in women
	Increased susceptibility for HIV and increased HIV shedding
	Produces vaginitis, cervicitis, urethritis, PID, and preterm, LBW babies
	Strawberry-colored cervix and fiery red vaginal mucosa with greenish, frothy discharge
	Diagnosis: Nucleic acid amplification test has the highest sensitivity and specificity; culture, monoclonal fluorescent antibody staining; whereas oral and rectal tests are not recommended
	Treatment: metronidazole (both partners)

Credits: (top to bottom) Biophoto Associates/Science Source; Collection CNRI/Phototake, Inc.; Dr. M.A. Ansary/Science Source

© DeVry/Becker Educational Development Corp. All rights reserved.

18 Types of Breast Cancer

- Malignant breast carcinoma is a common occurrence in postmenopausal women, usually arising from the terminal duct/lobular unit.
- Malignant breast carcinoma is most commonly discovered in the outer-quadrant of the breast due to increased amounts of dense connective tissue.
- Metastasis to the axillary lymph node is the single most important prognostic indicator.
- Risk factors include increased estrogen exposure, with increased total number of menstrual cycles, older age of first live birth, obesity, and genetic mutations in BRCA-1,2.
- Tests performed on samples of breast tissue:
  - S phase fraction above 5% is poor prognosis.
  - DNA ploidy (diploid tumor has a better prognosis than an aneuploidy tumor).
  - Overexpression of c-erbB2 (HER-2/neu, which is a human epidermal growth factor receptor) and topoisomerase II α are indicators of breast carcinoma with low survival rates.

Important Concept

Comedocarcinoma

This is a subtype of **ductal** carcinoma in situ, which is defined as a central ductal area of caseous necrosis surrounded by malignant cells.

▼Table 18–18.0 Types of Breast Cancer

Noninvasive	
Ductal carcinoma in situ (DCIS) 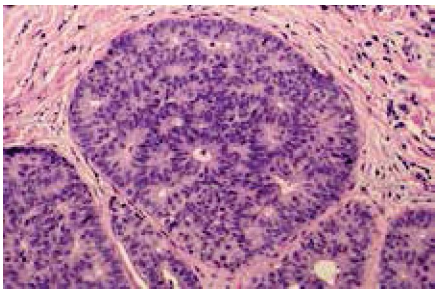	Nonpalpable patterns: cribriform (sieve-like), comedo (necrotic center)
	Commonly contain **microcalcifications;** cannot be detected by mammogram unless microcalcifications are present
	One third eventually invade
	Treated with "lumpectomy"
Lobular carcinoma in situ 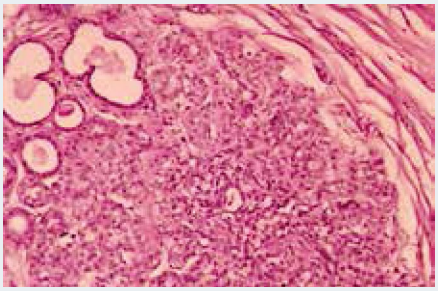	Nonpalpable; virtually always an incidental finding in a breast biopsy for other reasons; cannot be identified by mammography
	Lobules distended with bland neoplastic cells; one third eventually invade; usually **estrogen and progesterone receptor positive**
	Lobular carcinoma in situ is a precancerous lesion carrying an increased risk for invasive type of lobular carcinoma either in the ipsilateral or contralateral breast

Credits (top to bottom): Dr. Gladden Willis/Visual's Unlimited, Inc.; Custom Medical Stock Photo

© DeVry/Becker Educational Development Corp. All rights reserved.

▼Table 18–18.0 Types of Breast Cancer *(continued)*

Invasive	
Infiltrating ductal carcinoma	Stellate morphology, indurated, gray-white tumor One third have amplification of **ERBB2 oncogene**
	Gritty on cut section
	Induration caused by reactive fibroplasia (desmoplasia)
Paget disease of nipple 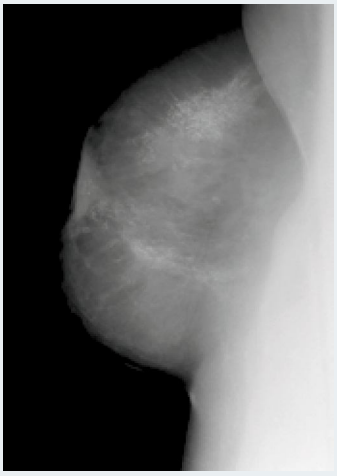	**Extension of DCIS into lactiferous ducts and skin of nipple, producing a rash with or without nipple retraction**
	Paget cells are present
	Palpable mass present in 50% to 60%
Inflammatory carcinoma	Erythematous breast with dimpling like an orange (peau d'orange) due to fixed opening of the sweat glands, which cannot expand with lymphedema
	Plugs of tumor blocking lumen of dermal lymphatics cause localized lymphedema
	Very poor prognosis
	Combination chemotherapy followed by surgery and irradiation
Medullary carcinoma	As the name implies, bulky soft tumor with large cells and a lymphoid infiltrate
	Majority are negative for estrogen and progesterone receptors
	There is, however, an association with BRCA1 mutations

Credits (top to bottom): Bolershot Photo/Science Source; Wellcome Images; B. Slaven, MD/Custom Medical Stock Photo

© DeVry/Becker Educational Development Corp. All rights reserved.

▼Table 18–18.0 Types of Breast Cancer *(continued)*

Invasive	
Invasive lobular carcinoma 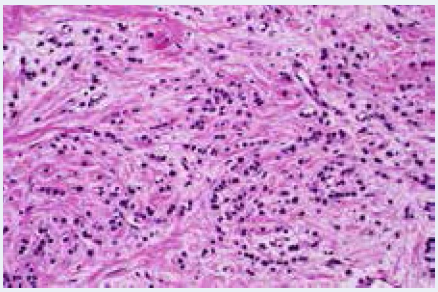	This cancer, as stated previously, may develop in the contralateral breast in a patient with lobular carcinoma in situ in 5%–10% of cases
	The neoplastic cells are arranged linearly or in concentric circles, bull's-eye appearance, in the stroma
Tubular carcinoma	These will develop in the terminal ductules with a 10% chance of developing cancer in the contralateral breast
Colloid (mucinous) carcinoma	This type is usually found in elderly women where the neoplastic cells are surrounded by extracellular mucin

Credits: Dr. Gladden Willis/Visuals Unlimited, Inc.

© DeVry/Becker Educational Development Corp. All rights reserved.